Diagnostic Challenges in Pulmonary Infection

Grace Y. Lin, M.D., Ph.D.

Where discoveries are delivered.℠

UC San Diego Health System

- No disclosures

UC San Diego Health System

Case Presentation

- 72 year old male with history of gastroesophageal reflux disease who is referred from outside hospital for evaluation of abnormal chest CT
- Initially patient evaluated at outside institution for enlarged neck lymph nodes.
- Laryngoscopy was unremarkable

UC San Diego Health System

Clinical presentation

- Past medical history – gastroesophageal reflux disease, vitiligo, non-melanoma skin cancer
- Past surgical history – Knee replacement
- Social history – non-smoker, but wife was smoker. Lived in Mexico previously, prior to moving to San Diego
- Physical exam – Skin shows vitiligo
- CT of the neck showed an incidental right upper lobe nodule that prompted additional CT chest and PET scans

UC San Diego Health System

CT Neck – Right upper lobe lesion

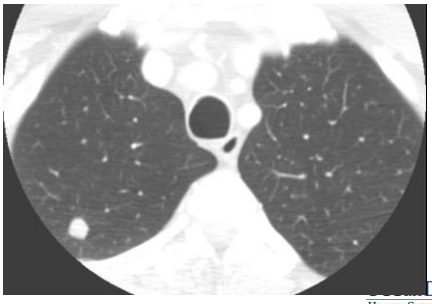

Health System

CT Chest and PET- Right upper lobe lesion

0.9 x 0.9 cm nodule – unchanged compared to prior head neck CT 3 months prior

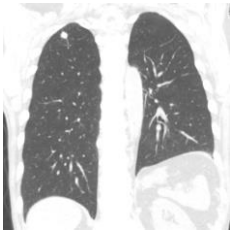

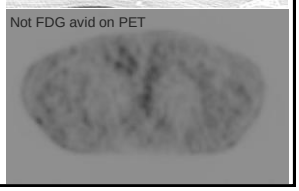

CT Chest and PET- Right middle lobe lesion

1.4 x 1.2 cm slightly spiculated nodule

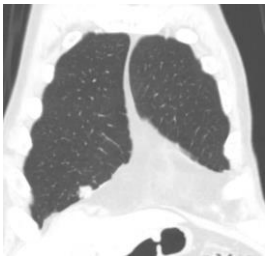

PET- FDG avid

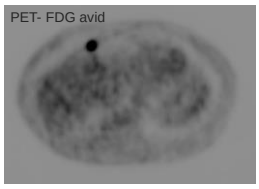

CT Chest and PET- Right lower lobe lesion

Lobulated nodule – 1.6 x 2.1 cm

PET- FDG avid

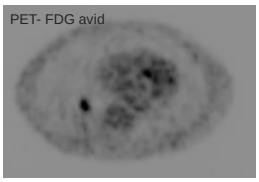

Three wedge biopsies were then performed Right middle lobe lesion – 1.0 x 1.0 x 0.8 cm

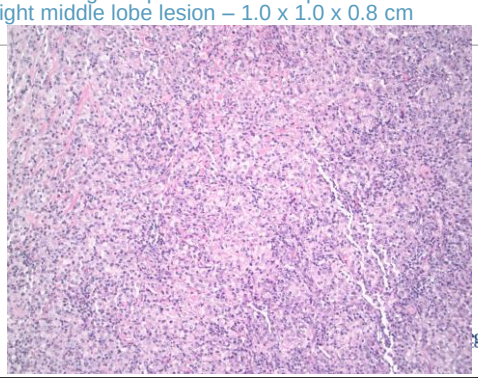

Right middle lobe lesion

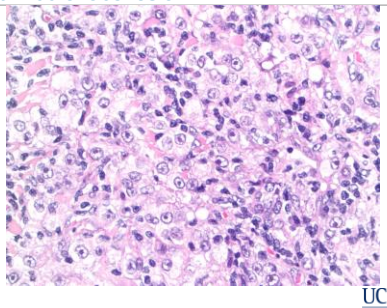

UC San Diego Health System

Right middle lobe tumor - Immunostaining

- Negative for Pan-keratin, SALL-4, Pan-LCA, CD15, CD30, CD1a, CD20, CD3, CD5, and Pax-5

HMB-45

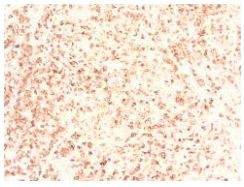

Mart-1

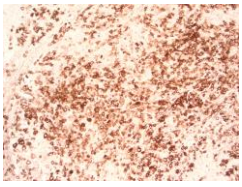

Also positive for S100

Metastatic melanoma

UC San Diego Health System

Right lower lobe lesion – 2.1 x 1.3 x 0.7 cm nodule

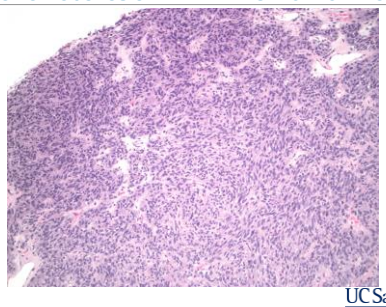

UC San Diego Health System

Right lower lobe lesion

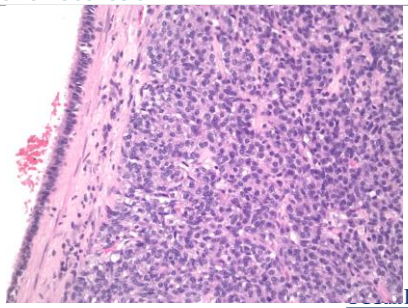

Right lower lobe lesion

- No mitotic figures or areas of necrosis identified.

Chromogranin

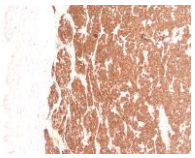

Synaptophysin

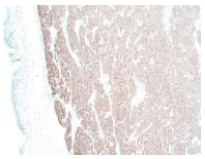

Also positive for pan-keratin, CD56, and neuron specific enolase (NSE).
Negative for S-100.

Carcinoid tumor

Right upper lobe - 1.0 x 1.0 x 0.8 cm

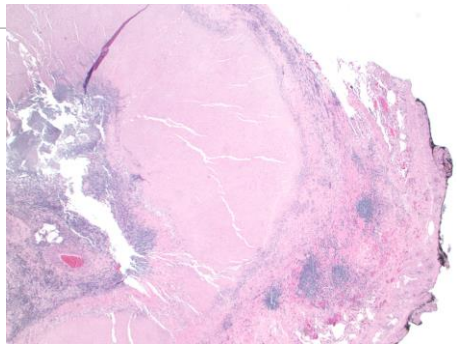

Right upper lobe nodule

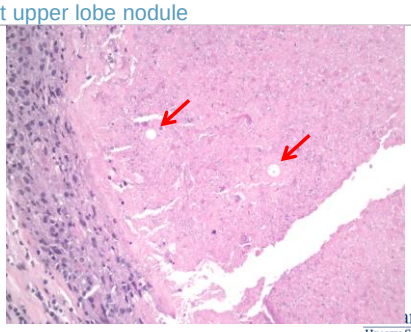

Right upper lobe nodule

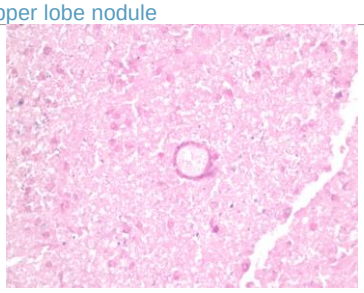

Right upper lobe nodule

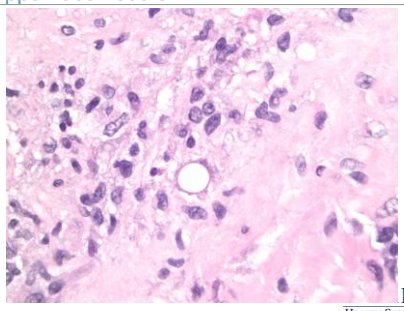

Right upper lobe nodule – GMS stain
10 to 100 micron spherules

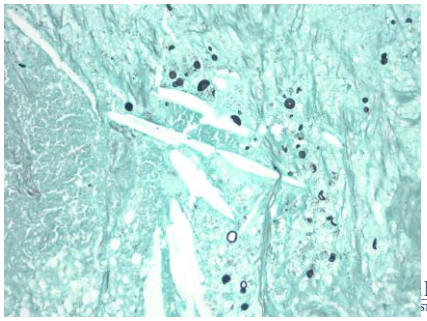

Right upper lobe nodule – GMS stain
Some spherules with internal septation

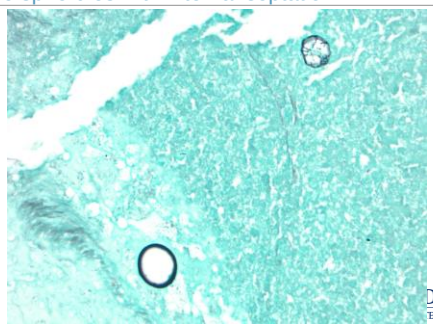

Right upper lobe nodule – GMS stain
Spherule with endospores

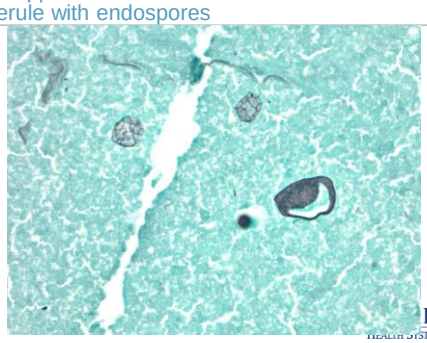

Lactophenol Cotton Blue stain of colonies from right upper lobe lesion culture

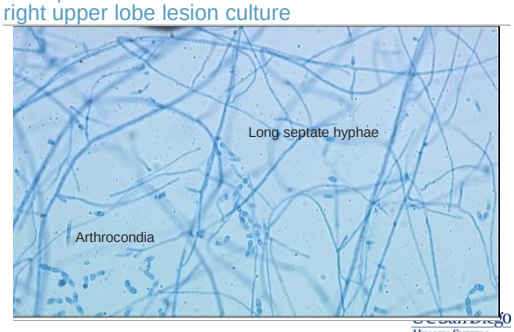

Lactophenol Cotton Blue stain of colonies from right upper lobe lesion culture

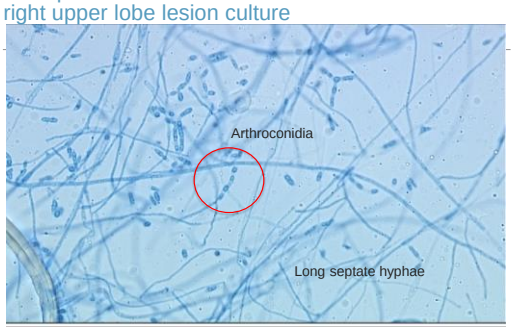

UC San Diego
Health System

Right upper lobe nodule

- Diagnosis: Necrotizing granulomatous inflammation due to Coccidioidomycosis
- Coccidioidomycosis due to *Coccidioides immitis* and *Coccidioides posadasii*
- Also known as Valley Fever, San Joaquin Valley Fever

- *Coccidioides spp.* are dimorphic fungi that grow as a mold in the soil
- Coccidioidomycosis is most commonly due to inhalation of *Coccidioides* arthroconidia from the soil and rarely due to introduction through the skin by a sharp object

UC San Diego
Health System

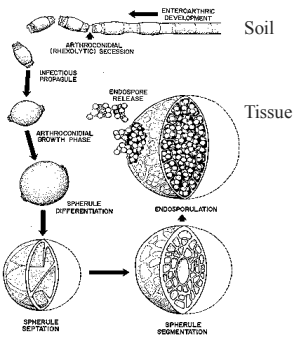

Courtesy Dr. Theo Kirkland, Department of Pathology and Medicine, Department of Veterans Affairs, San Diego, CA

UC San Diego Health System

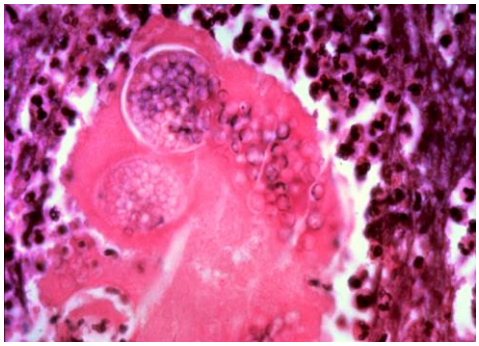

Courtesy Dr. Theo Kirkland, Department of Pathology and Medicine, Department of Veterans Affairs, San Diego, CA

UC San Diego Health System

Arthroconidia

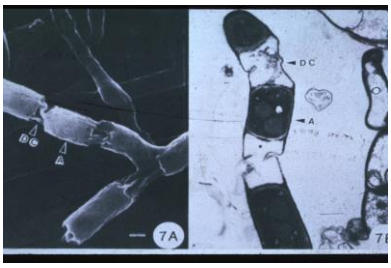

Courtesy Dr. Theo Kirkland, Department of Pathology and Medicine, Department of Veterans Affairs, San Diego, CA

UC San Diego Health System

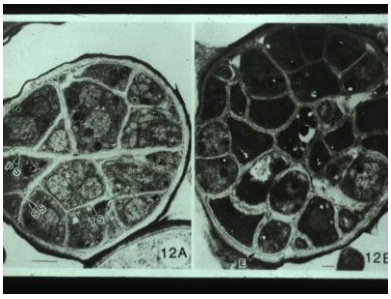

Courtesy Dr. Theo Kirkland, Department of Pathology and Medicine, Department of Veterans Affairs, San Diego, CA

UC San Diego Health System

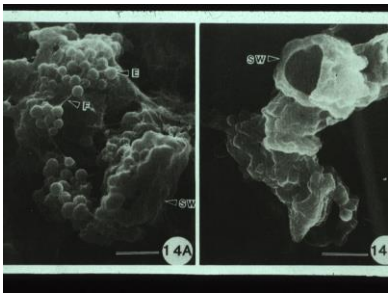

Courtesy Dr. Theo Kirkland

UC San Diego Health System

Coccidioides spp.

- Endemic in the southwest United States, Mexico, central America and South America (including Argentina, Colombia, Paraguay and Venezuela)
- Cases have been reported in many countries around the world in people who have travelled to endemic areas.

UC San Diego Health System

From the CDC

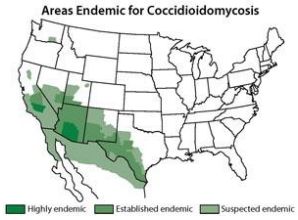

FIGURE 2. Average annual rate* of reported cases of coccidioidomycosis, by county — California, 2000–2007†

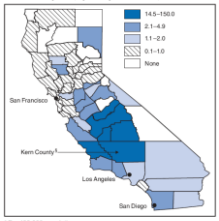

* Per 100,000 population.
† Data on reported cases are from California Department of Public Health Confidential Morbidity Reports. County population data are from California Department of Finance population projections.
§ Kern County, located in the San Joaquin Valley region, where coccidioidomycosis is endemic, had the highest rate among counties (150.0 cases per 100,000 population).

http://www.cdc.gov/fungal/diseases/coccidioidomycosis/causes.html

UC San Diego Health System

Coccidioides transmission

- Incidence in highest in the late summer and early fall when the soil is dry
- Outbreaks occur after events that disturb a large amount of soil such as earthquakes and large dust storms
- Past outbreaks have occurred in military trainees and archeological workers

UC San Diego Health System

From the CDC

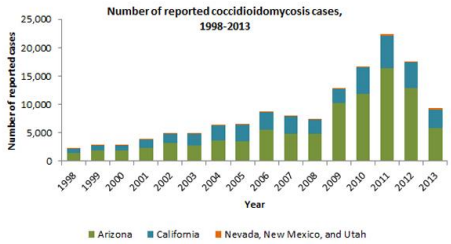

Approximately 200 deaths per year

UC San Diego Health System

Coccidioides incidence

- The etiology of the rise in incidence in 2010-2013 is not known
  - Environmental factors such as drought, rainfall, temperature
  - Increased disruption of soil due to construction
  - Changes in surveillance or reporting methodology
  - Increase in diagnostic testing due to increasing awareness
    - In endemic areas, an estimated 15-29% of cases of community acquired pneumonia are thought to be due to Coccidioides but a 2006 study showed that only 2-13% of patients were tested

UC San Diego Health System

Clinical presentation

- Most cases are likely asymptomatic and resolve spontaneously in the immunocompetent
- Symptomatic in 35-60%
  - Most people have non-specific flu-like symptoms (fever, cough, headache, skin rash, muscle aches, joint pain, fatigue)
  - Acute pneumonia
  - Chronic progressive pneumonia
  - Pulmonary nodules and cavities
- About 5% linger or disseminate
  - Disseminated extrapulmonary non-meningeal disease including miliary disease, bone and joint infection, skin disease, soft tissue abscesses
  - Meningitis

UC San Diego Health System

Who gets disseminated Coccidioidomycosis?

- Hospitalization rates highest among the following groups over the last several decades:
  - African American (10-127x increased risk of disseminated Coccidiodomycosis)
  - Filipinos
  - Males 50 years or older
  - Pregnant women
  - Immunosuppressed patients including patients with AIDS, Hodgkin lymphoma or other lymphoma, organ transplants
- Asymptomatic immune patients tend to have a strong delayed-type hypersensitivity response (T-cell mediated) and with low levels of complement-forming antibodies
- Severe disease is usually found in those with low delayed-type hypersensitivity response and high titers of complement-forming antibodies

UC San Diego Health System

Diagnosis

- Radiographic examination but nodules may be misdiagnosed as lung cancer
- Serology – enzyme immunoassay (EIA) testing; however, there may be a significant false positive rate (very sensitive, but not very specific)
- Sputum culture
- Biopsies
- Joint effusions
- Lumbar punctures

UC San Diego Health System

Common patterns of lung injury associated with Coccidioides

- Early lesions tend to be associated with neutrophilic inflammation
- Necrotizing granulomas
- Occasional eosinophilia (including in peripheral blood)
- Some cases with pleuritis, frequently fibrinous, sometimes with neutrophils and/or eosinophils and/or granulomas
- Cavitary lesions which may contain spherules and/or hyphae

UC San Diego Health System

Cultures

- Coccidioides spp. grow on Sabroud-dextrose agar, brain-heart infusion agar, potato dextrose agar, and blood agar
- 5-10 days to grow, initially white highly filamentous aerial colony which then turns tan
- Confirmation via molecular methods

- CDC recommendations:
- Patient specimens and tissue may be handled in Biosafety (BSL)-level 2 labs
- Sporulating cultures should be handled in BSL-3 labs (double door entry to lab, negative pressure room, biosafety cabinet)

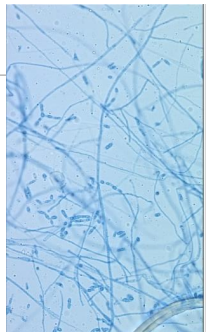

UC San Diego Health System

Treatment

- Most people do not need treatment
- Those with chronic pulmonary or disseminated disease may require anti-fungal therapy

UC San Diego Health System

Acknowledgements

- Dr. Andrew Yen for the radiology images
- Dr. David Pride for the images from the cultures
- Dr. Theo Kirkland for the electron microscopy images and schematics

References

1. Increase in Reported Coccidioidomycosis – United States, 1998-2011. *MMWR*. 2013; 62: 217-221.
2. http://www.cdc.gov/fungal/diseases/coccidioidomycosis/statistics.html
3. T.N. Kirkland and J. Fierer. Coccidioidomycosis: A Reemerging Infectious Disease. *Emerging Infectious Disease*. 1996; 3:192-199.
4. L. Johnson et al. Valley Fever: Danger Lurking in a Dust Cloud. *Microbes and Infection*. 2014; 16:591-600.

UC San Diego Health System